

Cerebral venous air embolism treated with hyperbaric oxygen: a case report

Pieter A Bothma, Andreas E Brodbeck and Bruce A Smith

Abstract

(Bothma PA, Brodbeck AE, Smith BA. Cerebral venous air embolism treated with hyperbaric oxygen: a case report. *Diving and Hyperbaric Medicine*. 2012;42(2):101-103.)

We present a case of cerebral venous gas embolism. Our patient made a complete neurological recovery after hyperbaric oxygen therapy (HBOT). The principles of HBOT, compressing and eliminating air bubbles and decreasing β -2 integrin function, thus improving microcirculation, can only be beneficial in a situation where neurological damage is likely. Retrograde cerebral venous gas embolism is a less well recognised variant of gas embolism than the arterial variant. Its existence as a different entity is better recognised in the forensic medicine and radiology literature than in other disciplines. There is evidence in the literature of patients dying from this complication and others seemingly experiencing very little effect. This case report highlights this condition, to encourage others to look out for it and report outcomes, and to serve as a reminder that peripheral lines may be a potential cause of gas embolism, although the portal of air entry in our case remains uncertain.

Key words

Venous gas embolism, hyperbaric oxygen therapy, medical conditions and problems, radiological imaging, right-to-left shunt, case reports

Introduction

Gas embolism is a serious complication of diving and is nowadays more commonly encountered as an iatrogenic complication of invasive medical procedures.¹⁻³ In most instances air is the gas involved.¹ Gas can be introduced into either the venous or arterial circulation. Hyperbaric oxygen therapy (HBOT) is recognised as the most effective treatment for cerebral arterial gas embolism.³ The role of HBOT in cerebral venous gas embolism (VGE) is still to be established. VGE is well known to occur as a result of central venous line insertion, or its accidental disconnection or removal when incorrect techniques are used.¹ A less well recognised source of VGE is peripheral venous access.^{4,5}

Paradoxical gas embolism occurs when gas passes from the right-sided circulation to the left side via an intra-cardiac shunt, e.g., most commonly a patent foramen ovale (PFO) or, in the absence of that, a presumed physiological or pathological arterio-venous pulmonary shunt.^{2,6} Such paradoxical emboli would be distributed throughout the systemic circulation but would preferentially circulate to areas of high blood supply, e.g., the cerebral and coronary vessels with life-threatening ischaemia if cardiovascular collapse is not fatal in itself.¹

We present a case of cerebral VGE of uncertain aetiology, discussing possible ports of entry of gas into the circulation as well as the diagnosis and management of this case. We will emphasise the awareness of retrograde cerebral venous air embolism as a yet poorly recognised variant of a well-known phenomenon.

Case report

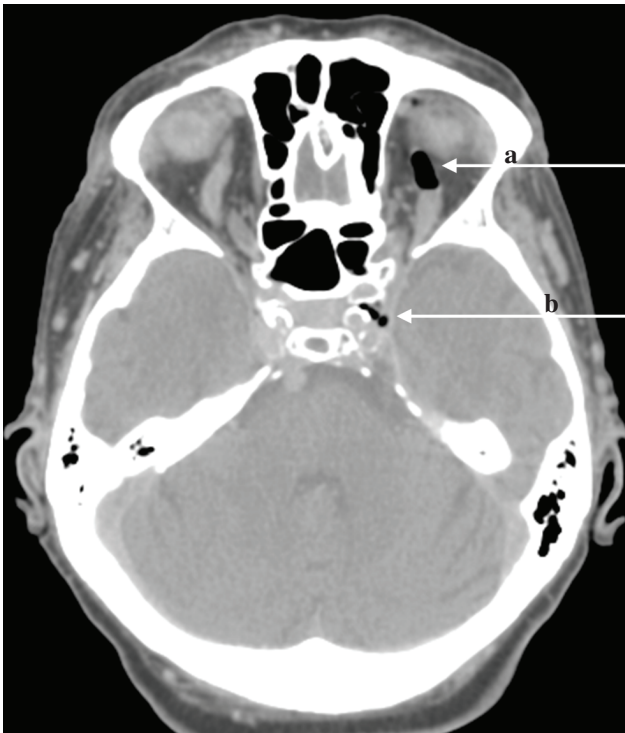
A 74-year-old female patient was admitted to the Emergency Department with suspected septic shock as a result of pneumonia. She had been found in a semi-comatose state on the floor of her flat. She had apparent renal failure as a result of rhabdomyolysis from lying on the floor for a long time. She had no lateralising neurological signs at that stage.

She was fluid resuscitated via two large-bore peripheral cannulae. When she was referred to ICU, she remained hypotensive and dyspnoeic with obviously distended neck veins. Initially her breathing was supported with non-invasive ventilation by face mask. An inspiratory pressure of 10 mmHg and positive end expiratory pressure of 5 mmHg was used. An arterial cannula was inserted in the right radial artery and a left internal jugular central line inserted with the patient supine. Both procedures were straightforward. The central line was inserted with ultrasound guidance, showing a dilated central venous system confirming the clinical impression of high venous pressure. The first measurement of central venous pressure was 18 mmHg. An infusion of noradrenaline was started immediately through the central line and tracheal intubation was performed to be able to control ventilation. A nasogastric tube was inserted, as well as a haemocath in the left femoral vein under ultrasound guidance for haemofiltration and a PiCCO® line for cardiac output studies in the right femoral artery.

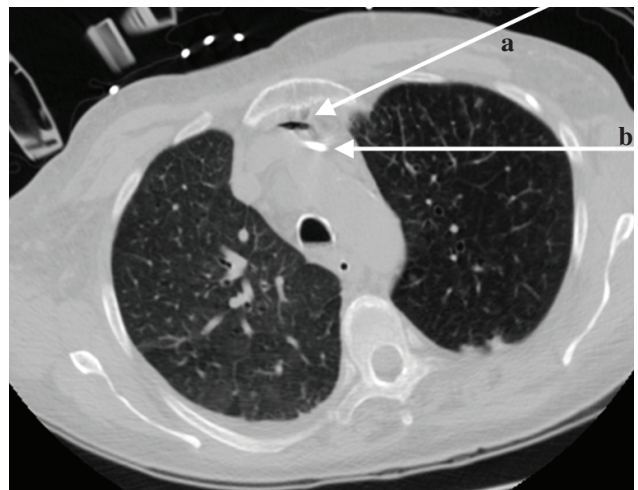
The patient's condition stabilised and she started passing urine once her blood pressure improved, obviating the need for immediate renal replacement therapy. She became

Figure 1

Air in the ophthalmic vein (a) and central venous sinus (b)

**Figure 2**

Air in the brachiocephalic vein (a) just anterior to a central venous line (white, b)



more stable haemodynamically and could be ventilated in the 45° head-up position to decrease the risk of aspiration pneumonia.^{7,8} The next morning, her sedation was stopped for neurological assessment. It was then clear that she had a right hemiparesis. She also had bilateral extensor plantar reflexes. A computerised tomographic (CT) brain scan ruled out an intracerebral bleed, but gas emboli could be detected in the intracranial blood vessels (Figure 1) and after contrast was given, gas emboli were clearly seen in the cerebral venous system as well as the left subclavian, internal jugular and brachiocephalic veins (Figure 2).

A CT scan of the chest excluded occult pneumothorax. The patient was then taken to the hyperbaric unit where she was treated with a US Navy Table 6 treatment protocol with full ICU monitoring and still on a noradrenalin infusion. This was followed by three further hyperbaric sessions using a US Navy Table 5 protocol, at which time the patient's neurological signs had apparently resolved. Her further progress was slow as a result of chronic lung disease (bronchiectasis and chronic obstructive pulmonary disease). She required a tracheostomy and prolonged weaning with separation from the ventilator after 41 days and was discharged from ICU after 49 days to the rehabilitation ward, being neurologically completely intact but very weak. She was eventually discharged from hospital to suitable nursing-home accommodation.

Discussion

The portal of gas entry into the venous system of our patient is uncertain. The central line insertion technique was impeccable and the patient had high venous pressure at that stage. This could be related to vigorous fluid resuscitation or it reflected right heart strain from air embolism. Partial disconnection of venous lines at a later stage could not be ruled out. Malfunction of the needle-free connectors attached to the central line was an unlikely possibility, but was excluded in view of previous warnings by the Medicines and Healthcare Products Regulatory Agency.⁹ Peripheral lines could be a portal of entry of air into the venous system, even when injecting contrast during CT imaging, and is often overlooked.^{4,5} The CT scans of the brain and chest ruled out the possibility of head trauma or a pneumothorax as the cause of air embolism, leaving the various vascular access ports and their connections as the alternative and most likely cause. Ongoing air entrainment from an underlying pulmonary condition is extremely unlikely as the patient remained on positive-pressure ventilation for a long time without recurrence of any neurological abnormality.

Cerebral gas embolism with neurological damage is usually assumed to be caused by obstruction of the arterial blood supply to parts of the brain. It is now evident that cerebral VGE could also cause significant morbidity and even mortality.¹⁰⁻¹² Cerebral air embolism has traditionally been assumed to result from direct arterial access or paradoxical embolism from the venous side through a PFO or pulmonary capillary filtration overload or arterio-venous malformation. Retrograde access of gas to the cerebral venous system has been ignored, possibly being regarded as innocuous.¹⁻³ Since the first description of cerebral VGE in 1991, this has been

recognised more frequently, and published, but not taught or described routinely.^{1-4,10,12-15}

Differentiating retrograde cerebral VGE from paradoxical cerebral arterial gas embolism is not only of academic importance and the former is certainly not innocuous.¹⁰⁻¹² With arterial gas embolism, small quantities of gas could theoretically immediately cause ischaemia in an area of brain distal to obstruction of small arteries. This necessitates urgent treatment with HBOT as soon as the patient's condition has been stabilised, despite the fact that some reported cases had good outcomes even after 30 hours' delay in treatment.^{1,2} With retrograde cerebral VGE there is no immediate arterial obstruction causing ischaemia. This may be a slow collection of gas depending on differential pressures in the cerebral venous and thoracic systems, blood flow rate and position of the patient's head above the heart.¹³⁻¹⁵ The inflammatory response between gas bubbles and the endothelium may lead to activation of neutrophils with β -2 integrin adhesion to endothelial cells, resulting in stasis and venous infarction. This biochemical process, however, may allow more time to arrange HBOT. Lack of early symptoms should not be regarded as a sign of lack of severity, as several cases with poor outcomes have been reported.^{10-12,15} Lastly, the importance of accurate diagnosis for medicolegal purposes cannot be overemphasised.¹⁴

Conclusions

Venous gas embolism is a well-known phenomenon. Gas emboli accumulating in the cerebral venous system and its consequences are fairly unknown and poorly understood variants. It is clear from the literature that patients have died from this. When a patient presents with cerebral VGE and neurological signs, it would be foolhardy not to offer HBOT. When the diagnosis is made in an asymptomatic patient, the management is uncertain. Careful neurological follow up may be adequate, but if available, HBOT may avoid late complications. Documenting and reporting such cases may help with future decision making.

Acknowledgements

Written consent was obtained from the patient to publish details of her case. No external funding was received for this work and no conflict of interest is declared.

References

- Muth CM, Shank ES. Gas embolism. *N Engl J Med*. 2000;342:476-82.
- Fukaya E, Hopf HW. HBO and gas embolism. *Neurol Res*. 2007;29:142-5.
- Trytko BE, Bennett MH. Arterial gas embolism: A review of cases at Prince of Wales Hospital, Sydney, 1996 to 2006. *Anaesth Intensive Care*. 2008;36:60-4.
- Rubinstein D, Dangleis K, Damiano TR. Venous air emboli identified on head and neck ct scans. *J Comput Assist Tomogr*. 1996;20:559-62.
- Groell R, Schaffler GJ, Rienmueller R. The peripheral intravenous cannula: A cause of venous air embolism. *Am J Med Sci*. 1997;314:300-2.
- Butler BD, Hills BA. Transpulmonary passage of venous air emboli. *J Appl Physiol*. 1985;59:543-7.
- Dellinger RP, Levy MM, Carlet JM, Bion J, Parker MM, Jaeschke R, et al. Surviving sepsis campaign: International guidelines for management of severe sepsis and septic shock. *Crit Care Med*. 2008;36:296-327.
- Drakulovic M, Torres A, Bauer T. Supine body position as a risk factor for nosocomial pneumonia in mechanically ventilated patients: A randomised trial. *Lancet*. 1999;354:1851-8.
- Medicines and healthcare products regulatory agency. *Medical device alert: needle-free intravenous connectors*. All manufacturers (mda/2011/068). [cited 8 September 2011 Sept 8]. Available from: <http://www.mhra.gov.uk/Publications/Safetywarnings/MedicalDeviceAlerts/CON120328>.
- Brouns R, De Surgeloose D, Neetens I, De Deyn PP. Fatal venous cerebral air embolism secondary to a disconnected central venous catheter. *Cerebrovasc Dis*. 2006;21:212-4.
- Ferry T, Argaud L, Robert D. Inactive tuberculosis cavity responsible for fatal cerebral air embolism. *Intensive Care Med*. 2006;32:622-3.
- Ploner F, Saltuari L, Marosi MJ, Dolif R, Salsa A. Cerebral air emboli with use of central venous catheter in mobile patient. *Lancet*. 1991;338:1331.
- Schlimp CJ, Lederer W. Factors facilitating retrograde cerebral venous air embolism - correspondence. *J Child Neurol*. 2008;23:973.
- Schlimp CJ, Loimer T, Rieger M, Lederer W, Schmidts MB. The potential of venous air embolism ascending retrograde to the brain. *J Forensic Sci*. 2005;50:906-9.
- Fracasso T, Karger B, Schmidt PF, Reinbold WD, Pfeiffer H. Retrograde venous cerebral air embolism from disconnected central venous catheter: An experimental model. *J Forensic Sci*. 2011;56:S101-S4.

Submitted: 08 December 2011

Accepted: 09 February 2012

Pieter A Bothma, FCA(SA), and Andreas E Brodbeck, MD, are consultants in the Department of Anaesthesia, Intensive Care and Hyperbaric Medicine, James Paget University Hospital, Great Yarmouth, UK.

Bruce A Smith, FCRad(SA)Diag, is a consultant in the Department of Radiology, James Paget University Hospital, Great Yarmouth, UK.

Address for correspondence:

Dr Pieter Bothma

James Paget University Hospitals NHS Foundation Trust
Lowestoft Road, Gorleston
Norfolk, NR31 6LA
United Kingdom

Phone: +44-(0)1493-452-452

Fax: +44-(0)1493-452-753

E-mail: <pabothma@dsl.pipex.com>