

# A case of Löfgren's syndrome confused with decompression sickness

Payal S Razdan<sup>1,2</sup>, Dominique Buteau<sup>3,4</sup>, Neal W Pollock<sup>1,2</sup>

<sup>1</sup> Department of Kinesiology, Faculty of Medicine, Université Laval, Québec, Canada

<sup>2</sup> CISSS Chaudière-Appalaches (CHAU-Hôtel-Dieu de Lévis), Hyperbaric Medicine Unit, Lévis, Québec, Canada

<sup>3</sup> Family Medicine and Emergency Medicine Department, Faculty of Medicine, Université Laval, Québec, Canada

<sup>4</sup> CISSS Chaudière-Appalaches (CHAU-Hôtel-Dieu de Lévis), Hyperbaric Medicine Unit, Emergency Department, Lévis, Québec, Canada

**Corresponding author:** Payal S Razdan, Rm 4807, Hôtel-Dieu de Lévis, 143 rue Wolfe, Lévis, QC, Canada, G6V 3Z1  
[payal.razdan@fmed.ulaval.ca](mailto:payal.razdan@fmed.ulaval.ca)

## Key words

Hyperbaric oxygen; Differential diagnosis; Mycobacterium marinum infection; Pulmonary sarcoidosis

## Abstract

(Razdan PS, Buteau D, Pollock NW. A case of Löfgren's syndrome confused with decompression sickness. *Diving and Hyperbaric Medicine*. 2019 December 20;49(4):306–310. doi: [10.28920/dhm49.4.306-310](https://doi.org/10.28920/dhm49.4.306-310). PMID: [31828751](https://pubmed.ncbi.nlm.nih.gov/31828751/).)

A broad differential diagnosis is important to provide appropriate care. This may be challenging for conditions like decompression sickness (DCS) which can be easily confused with other conditions. In suspected DCS, treatment may be an important part of the diagnosis. An improvement in symptoms after hyperbaric oxygen treatment (HBOT) is consistent with a DCS event. However, HBOT may also impact symptoms in other conditions, including Löfgren's syndrome (LS). LS, a poorly understood, clinically distinct phenotype of sarcoidosis, is a complex, multi-system granulomatous inflammatory condition. Like DCS, LS symptoms are heterogeneous and idiosyncratic. We report on a patient initially diagnosed with DCS who presented new symptoms suggestive of LS after HBOT.

## Introduction

Decompression sickness (DCS) is a syndrome associated with a reduction in ambient pressure that produces a supersaturation of dissolved inert gas. Excessive supersaturation may provoke bubble formation and lead to DCS. While the mechanisms are not fully elucidated, hyperbaric oxygen therapy (HBOT) is established as the definitive treatment. HBOT promotes inert gas elimination, increases tissue PO<sub>2</sub>, reduces inflammation, and promotes tissue healing.

Consideration of a broad differential diagnosis is important in determining appropriate treatment where DCS is suspected. Confirming DCS can be challenging due to idiosyncratic presentation and nonspecific manifestations. Clear understanding of patient history, signs and symptoms, and the level of decompression stress experienced are crucial in establishing the index of suspicion. Case management can be difficult when clinical suspicion is low.

Löfgren's syndrome (LS) is thought to be a clinically distinct phenotype of sarcoidosis; a complex, multi-system granulomatous inflammatory disease of unknown aetiology. Any organ may be affected, but most commonly the lungs.<sup>1</sup> LS may initially present with ambiguous constitutive symptoms and is often identified by acute presentation of the classic triad symptoms: bilateral arthritis/periarticular inflammation; erythema nodosum; and/or bilateral hilar

lymphadenopathy. Diagnosis is one of exclusion since it is easily confused with other infectious diseases. While the diagnosis is typically established with complementary clinical, radiological, and histological findings, the classic presentation of LS may be sufficient to make a presumptive diagnosis based on clinical manifestations.<sup>2</sup>

The following case describes a diver initially treated for DCS but later diagnosed with LS and stage II pulmonary sarcoidosis following acute symptom presentation post-HBOT. Challenges in differential diagnosis, unique clinical presentation, and the potential impact of HBOT on LS are discussed.

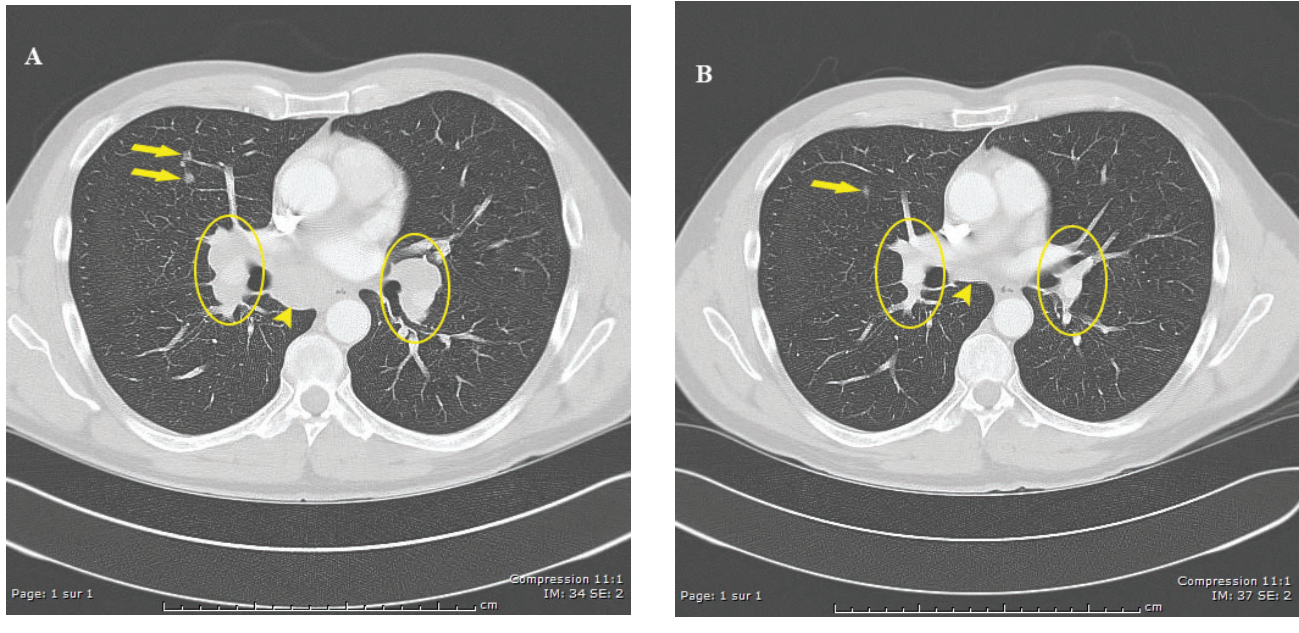
## Case presentation

The patient was a 53 year-old male diver, a relatively healthy non-smoking teetotaler, with a history of performing approximately 200 working dives in a public aquarium annually, generally to a maximum depth around 6 metres' sea water (msw) for 1 h. Equipment and supplies at the surface necessitated that dives typically followed a saw-tooth profile, however, only entry and exit times were recorded. He had not exceeded a depth of 7 msw in the three weeks prior to this event.

He first reported feeling unusual, unwell, fatigued, and cold over a three-week period prior to medical consultation. Symptoms progressed to include periodic shivering and

**Figure 1**

Axial computerized tomography scans of the chest (mediastinal window). Image (a) taken 19 days post-HBOT shows two nodules visible in the pulmonary parenchyma of the left lobe (marked by arrows), enlarged mediastinal lymphadenopathy (marked by arrow head), and bilateral hilar lymphadenopathy (marked by ovals). Image (b) was taken five months post-HBOT and demonstrates the regression of pulmonary nodules, mediastinal lymphadenopathy, and bilateral hilar lymphadenopathy



diffuse muscle aches. Pain reportedly began in the shoulders and migrated to the heels and ankles in the two weeks pre-consultation. Approximately one-week pre-consultation he experienced intense and piercing bilateral ankle pain. He continued to dive throughout and reported that the pain was reduced or almost eliminated at depth but returned approximately 90 min after surfacing.

His last dive pre-consultation was performed two days earlier, to a maximum depth of 7 msw for 65 min. Symptoms returned approximately 4–5 h later; bilateral pain primarily in the heels and ankles, but also in the wrists, elbows, hips, and in the dorsal region of the back. Pain continued to intensify until the morning of consultation (7/10 maximum), expressed bilaterally with marked difficulty walking. The patient contacted the provincial diving emergency medical hotline and was advised to seek further evaluation. After an initial emergency room evaluation, the patient was directed to the on-call hyperbaric physician. No indications of diminished neurological function were found upon examination.

No supplemental oxygen was administered prior to HBOT. Physical exam found normal vital signs and the possibility of minor bilateral wrist swelling. DCS was suspected and an United States Navy HBOT Table 6 (USN TT6) recompression was performed.<sup>3</sup> After 10 min at maximal pressure (284 kPa, 2.8 atmospheres absolute), the patient reported relief of pain. Paraesthesia in the right heel was eliminated. All pain was resolved following the USN TT6. Diving was prohibited for two weeks and 500 mg naproxen BID prescribed.

Three hours following the USN TT6 the patient experienced feeling cold with marked continuous shaking for approximately 20 min. A self-measured oral temperature of 37.8°C was later reported. He fell asleep and awoke 2 h later feeling tired but otherwise stable. Three days post-HBOT he noticed painful bilateral nodules on the anterior ankle and shin. Blood work assayed eight days post-HBOT indicated signs of inflammation and/or infection (Table 1). Nine days post-HBOT he reported feeling less pain but had acquired a dry cough.

Medical follow-up 11 days post-HBOT uncovered signs of acute arthritis in the ankles and appearance of painful anterior ankle and shin nodules. Rheumatology evaluation the following day was unremarkable for neck, cardiopulmonary, and abdominal exams, with bilateral periarticular ankle inflammation and erythema nodosum in the crural region. A pre-recompression chest X-ray showed a 15 mm nodular opacity in the inferior lobe of the right lung. The rheumatologist suspected LS and prescribed 50 mg indomethacin to be taken every 8 h.

The patient was evaluated by a lung specialist 19 days post-HBOT. Findings included a SpO<sub>2</sub> of 94%, mild dry cough, but no lymphatic swelling, shortness of breath, or visual disturbances. Synovitis in ankles and erythema nodosum remained. Thoraco-abdominal CT scan showed multiple pulmonary nodules and mediastinal and bilateral hilar lymphadenopathy (Figure 1a). There was no abdominal lymphadenopathy. Spirometric and carbon monoxide diffusion capacity were above predicted values.<sup>4</sup> Inflammatory markers returned to the normal range four

**Table 1**

Blood work results post-HBOT. Normal ranges are presented in parentheses in column one.<sup>19,20</sup> High (H) and low (L) identify measures that are considered outside of the normal range. NA identifies factors that were not measured

Measure (normal values)	Result	
	8 d	26 d
Erythrocytes (4.18–5.62 x10 <sup>12</sup> ·L <sup>-1</sup> ) <sup>19</sup>	4.56	4.56
Hemoglobin (134–173 g·L <sup>-1</sup> ) <sup>19</sup>	136	138
Hematocrit (0.39–0.50) <sup>19</sup>	0.400	0.401
Leukocytes (4.0–12.0 x10 <sup>9</sup> ·L <sup>-1</sup> ) <sup>19</sup>	9.2	7.4
Neutrophils absolute (4.3–7.5 x10 <sup>9</sup> ·L <sup>-1</sup> ) <sup>19</sup>	7.9 (H)	6.0
Lymphocytes absolute (1.6–4.4 x 10 <sup>9</sup> ·L <sup>-1</sup> ) <sup>19</sup>	0.6 (L)	0.7 (L)
Monocytes absolute (0.4–1.0 x10 <sup>9</sup> ·L <sup>-1</sup> ) <sup>19</sup>	0.6	0.6
Eosinophils absolute (0.06–0.8 x10 <sup>9</sup> ·L <sup>-1</sup> ) <sup>19</sup>	0.1	0.2
Basophils absolute (0.0–2.7 x10 <sup>9</sup> ·L <sup>-1</sup> ) <sup>19</sup>	0.0	0.0
Erythrocyte sedimentation rate (1–10 mm·h <sup>-1</sup> ) <sup>20</sup>	32 (H)	17 (H)
C-reactive protein (0.0–3.0 mg·L <sup>-1</sup> ) <sup>20</sup>	69.1 (H)	10.6 (H)
Albumin (59.1–70.1 g·L <sup>-1</sup> )	60.7	NA
Alpha-1 globulins (1.6–3.2 g·L <sup>-1</sup> )	4.0 (H)	NA
Alpha-2 globulins (8.0–12.6 g·L <sup>-1</sup> )	10.8	NA
Calcium (mmol·L <sup>-1</sup> )	NA	2.3
RA test (fixation latex)	Negative	NA

weeks after HBOT (Table 1). An ophthalmologic exam was unremarkable.

Eight weeks following HBOT the patient reported no symptoms and a chest X-ray showed signs of nodule regression. He was cleared for and resumed diving. He had no symptoms at the five-month follow up and a CT scan showed regression of mediastinal and hilar lymphadenopathies and a 50% volume reduction in many pulmonary nodules (Figure 1b). He remained symptom free at one-year post-HBOT, with normal size mediastinal lymph nodes, and lung tissue with only three small nodules, all with diameters less than 5 mm.

## Discussion

Delayed reporting of DCS symptoms is not unusual. There is also no diagnostic test to confirm DCS. The decision to treat with HBOT was possibly influenced by multiple factors: recent diving activity, presentation of symptoms consistent with DCS, lack of contraindications, and availability of HBOT. Nonspecific symptoms such as fatigue, malaise, and transient periarticular discomfort have been associated with DCS in approximately 40% of cases.<sup>5</sup> The pattern of symptom reduction during diving and return post-dive was consistent with DCS. There were, however, inconsistencies that make it unlikely that this was a DCS event.

Spinal cord DCS may present with bilateral motor deficits, and back pain, but it predominantly manifests immediately after surfacing and indicates severe DCS.<sup>6</sup> Patient and

physician reports suggest that the difficulty walking was more likely due to intense pain and fatigue than neurological decrement. Additionally, the patient's dive profiles were not provocative. The USN no-decompression limit for 8 msw is 1,102 min<sup>3</sup>, far greater than the patient's dive times, making DCS highly improbable.

Involvement of multiple joints bilaterally and migrating pain are also not common in DCS, although it is a notably unusual feature in LS. The 15 mm lung nodule documented pre-recompression by X-ray was characteristic of stage II sarcoidosis but its clinical relevance was not identified during the initial review. It was reported by the radiologist days after HBOT. Pulmonary nodules less than 30 mm are not uncommon and are typically benign,<sup>7</sup> thus not providing strong evidence for differential diagnosis. Skin lesion biopsies can help to verify LS,<sup>8</sup> but this patient did not initially present with erythema nodosum. The differential possibilities are broad and include infectious, toxic, and inflammatory agents. Acute presentation of the classic triad signs/symptoms after recompression and HBOT resulted in a new diagnosis of LS, stage II sarcoidosis.

The peak of immunological response in LS is often characterized by erythema nodosum at about three weeks after a precipitating stimulus (e.g., infection) and is associated with peak neutrophil counts.<sup>9</sup> Spontaneous recovery generally begins approximately six weeks after inoculation, with full recovery within two years. This typical disease course roughly paralleled the patient's experience in this case.

LS is associated with heightened abnormal immune responses to antigenic triggers in genetically susceptible individuals. While the cause was not confirmed in this case, mycobacterium, and particularly non-tuberculosis mycobacteria (NTM), has been associated with sarcoidosis.<sup>10,11</sup> NTM, such as *Mycobacterium marinum*, is found in both fresh and saltwater environments, and skin and pulmonary infections have been reported.<sup>12</sup> Human infection is possible with small cuts, abrasions, or following trauma. The site of infection is characteristically marked by a lesion. The risk of skin contact was possible in this case since the dive gear did not provide complete isolation. The patient also reported that *M. marinum* levels were higher than normal in the facility during the period when he became ill, although facility records were not made available.

No primary traumatic skin lesion was reported. However, aspiration of antigens has been suggested with pulmonary sarcoidosis-like infections. Certain occupations exposed to airborne antigens (e.g., healthcare and agriculture workers) are at increased risk.<sup>13</sup> It is possible that the lungs were the primary site of infection following aspiration of a waterborne bacterial antigen such as *M. marinum*. Potassium peroxymonosulfate (Virkon™ S), the disinfectant used to sterilize the diving equipment, may also have been a respiratory irritant. The impact of repeated exposure to Virkon™ S residue is unclear.

Limited information is available on the interaction between HBOT and LS. Pain attenuation following HBOT has been reported in chronic pain syndromes<sup>14</sup> and site specific oedema,<sup>15</sup> and may be associated with improvement in localized inflammation seen in conditions like rheumatoid arthritis.<sup>16</sup> Pain reduction in this patient may have been associated with attenuation of inflammation, localized oedema, and reduction in proinflammatory cytokines. Although pre-HBOT inflammatory measures were not collected, post-HBOT markers were elevated. While diving, pain relief may be associated with some combination of reduced joint load, compression from the diving wetsuit, increased hydrostatic pressure, and regional cooling.

HBOT for infections generally involves exposure to 243 kPa (2.4 atmospheres absolute) with the understanding that the increased PO<sub>2</sub> will lead to bactericidal effects.<sup>17</sup> HBOT reportedly promotes host defences such as improved bacterial targeting by leukocytes,<sup>18</sup> which were slightly elevated in this case post-HBOT (Table 1). It is possible that a combination of elevated oxygen partial pressure and high bacterial counts led to bacterial destruction and subsequent increased release of toxins into systemic circulation. This may have resulted in acute onset of constitutive and classic triad manifestations, and the report of marked shaking.

The case information had several limitations. Blood work was not performed prior to HBOT. Therefore, no measures were available for inflammatory or infectious factors pre-HBOT, making it difficult to evaluate the impact of LS

versus the possible effects of HBOT. Biopsies were not conducted, making it impossible to confirm the diagnosis of LS or to establish the presence of specific infectious agents. Documentation of *M. marinum* levels were not available from the diving facility.

## Conclusion

Both DCS and LS can present challenges for differential diagnosis. Careful consideration of the differential is critical in cases where presentation is atypical. The pulmonary nodule, along with ambiguous constitutive symptoms and the benign nature of the dive profiles, could raise the suspicion of sarcoidosis. It is reasonable to include sarcoidosis in the differential diagnosis of patients presenting with DCS-like symptoms.

## References

- Baughman RP, Teirstein AS, Judson MA, Rossman MD, Yeager HJ, Bresnitz EA, et al. Clinical characteristics of patients in a case control study of sarcoidosis. *Am J Respir Crit Care Med.* 2001;164:1885–9. doi: 10.1164/ajrcm.164.10.2104046. PMID: 11734441.
- Valeyre D, Bernaudin JF, Uzunhan Y, Kambouchner M, Brillet PY, Soussan M, et al. Clinical presentation of sarcoidosis and diagnostic work-up. *Semin Respir Crit Care Med.* 2014;35:336–51. doi: 10.1055/s-0034-1381229. PMID: 25007086.
- Navy Department. US Navy Diving Manual. Revision 7. Vol 5: Diving Medicine and Recompression Chamber Operations. NAVSEA 0910-LP-115-1921. Washington (DC): Naval Sea Systems Command; 2016. Available from: [https://www.navsea.navy.mil/Portals/103/Documents/SUPSALV/Diving/US%20DIVING%20MANUAL\\_REV7.pdf?ver=2017-01-11-102354-393](https://www.navsea.navy.mil/Portals/103/Documents/SUPSALV/Diving/US%20DIVING%20MANUAL_REV7.pdf?ver=2017-01-11-102354-393). [cited 2018 December 17].
- Verbankck S, Van Muylem A, Schuermans D, Bautmans I, Thompson B, Vincken W. Transfer factor, lung volumes, resistance and ventilation distribution in healthy adults. *Eur Respir J.* 2016;47:166–76. doi: 10.1183/13993003.00695-2015. PMID: 26585426.
- Vann RD, Butler FK, Mitchell SJ, Moon RE. Decompression illness. *Lancet.* 2011;377:153–64. doi: 10.1016/S0140-6736(10)61085-9. PMID: 21215883.
- Gempp E, Blatteau JE, Stephant E, Pontier JM, Constantin P, Pény C. MRI findings and clinical outcome in 45 divers with spinal cord decompression sickness. *Aviat Space Environ Med.* 2008;79:1112–6. PMID: 19070307.
- Anderson IJ, Davis AM. Incidental pulmonary nodules detected on CT images. *JAMA.* 2018;320:2260–1. doi: 10.1001/jama.2018.16336. PMID: 30419095.
- Mañá J, Gómez-Vaquero C, Montero A, Salazar A, Marcoval J, Valverde J, et al. Löfgren's syndrome revisited: a study of 186 patients. *Am J Med.* 1999;107:240–5. doi: 10.1016/s0002-9343(99)00223-5. PMID: 10492317.
- Schwartz RA, Nervi SJ. Erythema nodosum: a sign of systemic disease. *Am Fam Physician.* 2007;75:695–700. PMID: 17375516.
- Chen ES, Wahlström J, Song Z, Willett MH, Wikén M, Yung RC, et al. T cell responses to mycobacterial catalase-peroxidase profile a pathogenic antigen in systemic sarcoidosis. *J Immunol.* 2008;181:8784–96. doi: 10.4049/jimmunol.181.12.8784.

- PMID: 19050300. PMCID: PMC2700300.
- 11 Esteves T, Aparicio G, Garcia-Patos V. Is there any association between sarcoidosis and infectious agents?: a systematic review and meta-analysis. *BMC Pulm Med.* 2016;16(1):165. doi: 10.1186/s12890-016-0332-z. PMID: 27894280. PMCID: PMC5126827.
  - 12 De Groote MA, Johnson P. Skin, bone, and soft tissue infections. In: Pedley S, Bartram J, Rees G, Dufour A, Cotruvo JA, editors. *Pathogenic mycobacteria in water: a guide to public health consequences, monitoring, and management.* Geneva: World Health Organization; 2004. p. 104–14. Available from: [http://apps.who.int/iris/bitstream/handle/10665/42854/9241562595\\_eng.pdf;jsessionid=A4FFBD8340DEEABED4127BAA9EDBA889?sequence=1](http://apps.who.int/iris/bitstream/handle/10665/42854/9241562595_eng.pdf;jsessionid=A4FFBD8340DEEABED4127BAA9EDBA889?sequence=1). [cited 2019 January 2].
  - 13 Design of case control etiologic study of sarcoidosis (ACCESS). Access research group. *J Clin Epidemiol.* 1999;52:1173–86. PMID: 10580780.
  - 14 Sutherland AM, Clarke HA, Katz J, Katznelson R. Hyperbaric oxygen therapy: a new treatment for chronic pain? *Pain Pract.* 2016;16:620–8. doi: 10.1111/papr.12312. PMID: 25988526.
  - 15 Bosco G, Vezzani G, Mrakic Sposta S, Rizzato A, Enten G, Abou-Samra A, et al. Hyperbaric oxygen therapy ameliorates osteonecrosis by modulating inflammation and oxidative stress. *J Enzyme Inhib Med Chem.* 2018;33:1501–5. doi: 10.1080/14756366.2018.1485149. PMID: 30274530. PMCID: PMC6171420.
  - 16 Benson RM, Minter LM, Osborne BA, Granowitz EV. Hyperbaric oxygen inhibits stimulus-induced proinflammatory cytokine synthesis by human blood-derived monocyte-macrophages. *Clin Exp Immunol.* 2003;134:57–62. doi: 10.1046/j.1365-2249.2003.02248.x. PMID: 12974755. PMCID: PMC1808843.
  - 17 Memar MY, Ghotaslou R, Samiei M, Adibkia K. Antimicrobial use of reactive oxygen therapy: current insights. *Infect Drug Resist.* 2018;11:567–76. doi: 10.2147/IDR.S142397. PMID: 29731645. PMCID: PMC5926076.
  - 18 Park MK, Myers RA, Marzella L. Oxygen tensions and infections: modulation of microbial growth, activity of antimicrobial agents, and immunologic responses. *Clin Infect Dis.* 1992;14:720–40. doi: 10.1093/clinids/14.3.720. PMID: 1562664.
  - 19 Lim E, Miyamura J, Chen JJ. Racial/Ethnic-specific reference intervals for common laboratory tests: a comparison among Asians, blacks, Hispanics, and white. *Hawaii J Med Public Health.* 2015;74:302–10. PMID: 26468426. PMCID: PMC4578165.
  - 20 Bray C, Bell LN, Liang H, Haykal R, Kaikow F, Mazza JJ, et al. Erythrocyte sedimentation rate and C-reactive protein measurements and their relevance in clinical medicine. *WMJ.* 2016;115:317–21. PMID: 2909486.

#### Conflicts of interest and funding

Associate Professor Neal W Pollock is a member of the Editorial Board of *Diving and Hyperbaric Medicine*. He had no role in the review process or decision making in relation to this manuscript.

**Submitted:** 12 February 2019

**Accepted after revision:** 14 June 2019

**Copyright:** This article is the copyright of the authors who grant *Diving and Hyperbaric Medicine* a non-exclusive licence to publish the article in electronic and other forms.

---